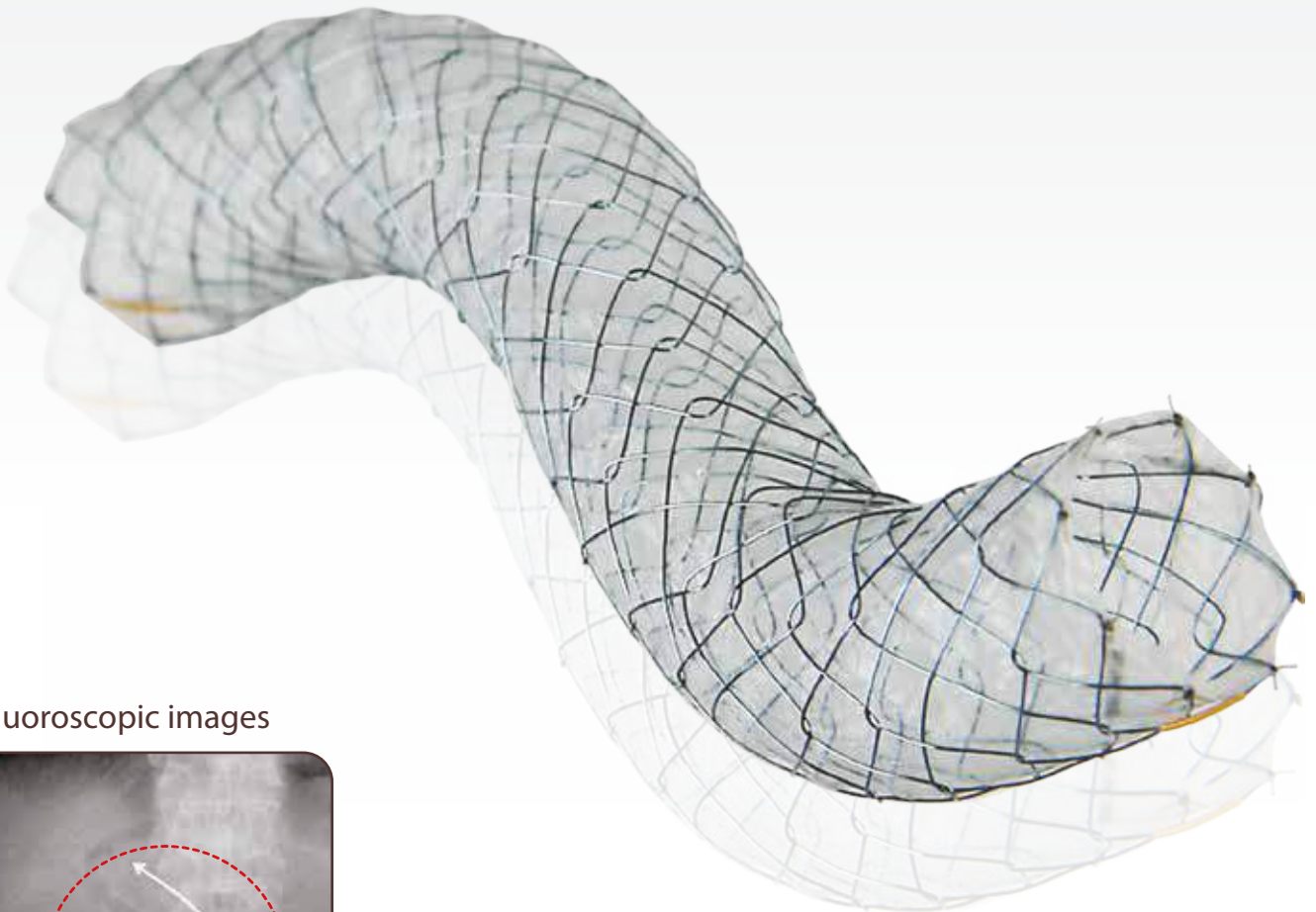
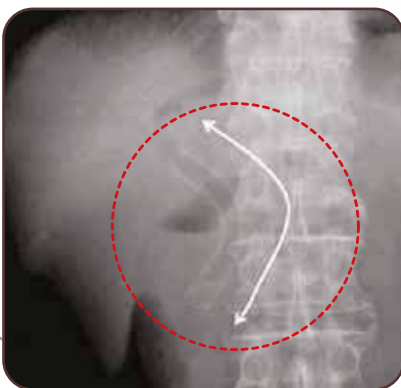




COMVI™ Biliary stent



■ Fluoroscopic images

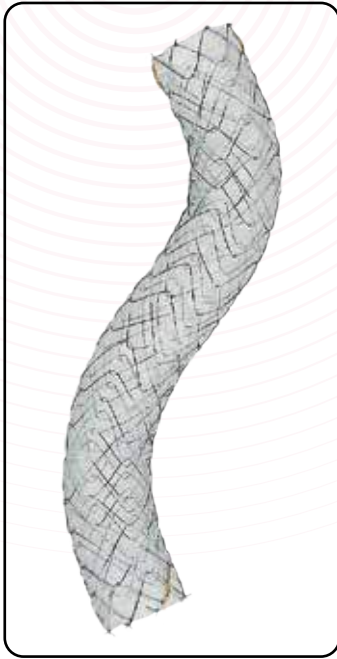


*"Plane abdominal X-ray 1 week after stent insertion.
The Comvi™ stent conforms to the shape of the bile duct."*

[Surg Endosc 11.June.2009, Hiroyuki Isayama]



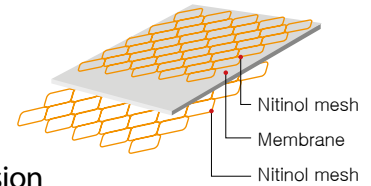
Taewoong Niti-S™ Comvi™ Biliary stent for malignant biliary strictures



● Features

Triple layered construction : Biocompatible PTFE membrane tube is held between inner and outer mesh

Triple layered construction



- PTFE membrane prevents risk of tissue invasion
- Outer wire mesh prevents the risk of migration
- Unfixed cell structure enables stent to conform to the shape of bile duct

● Radiopaque marker : 4(four) at both covered part ends

● Ordering Information

Endoscopic Approach

► Fully covered

Code	Stent		Delivery		
	Diameter (mm)	Length (cm)	Profile (Fr)	Usable Length (cm)	
BC0604F	6	4	8	180	
BC0605F		5			
BC0606F		6			
BC0607F		7			
BC0608F		8			
BC0609F		9			
BC0610F		10			
BC0612F		12			
BC0804F		8			4
BC0805F					5
BC0806F					6
BC0807F					7
BC0808F	8				
BC0809F	9				
BC0810F	10				
BC0812F	12				
BC1004F	10	4			
BC1005F		5			
BC1006F		6			
BC1007F		7			
BC1008F		8			
BC1009F		9			
BC1010F		10			
BC1012F		12			

Percutaneous Approach

► Fully covered

Code	Stent		Delivery		
	Diameter (mm)	Length (cm)	Profile (Fr)	Usable Length (cm)	
TC0604F	6	4	8	50	
TC0605F		5			
TC0606F		6			
TC0607F		7			
TC0608F		8			
TC0609F		9			
TC0610F		10			
TC0612F		12			
TC0804F		8			4
TC0805F					5
TC0806F					6
TC0807F					7
TC0808F	8				
TC0809F	9				
TC0810F	10				
TC0812F	12				
TC1004F	10	4			
TC1005F		5			
TC1006F		6			
TC1007F		7			
TC1008F		8			
TC1009F		9			
TC1010F		10			
TC1012F		12			

* Available both bare ends

Coding : BC**_B: 5mm bare

Released Articles

- * *Measurement of radial and axial forces of biliary self-expandable metallic stents* Gastrointestinal Endoscopy Vol 70, No.1: 2009 Hiroyuki Isayama
- * *Management of distal malignant biliary obstruction with the Comvi stent, a new covered metallic stent* Surg Endosc Springer Science+ Business Media, LLC 2009 Hiroyuki Isayama
- * *Prospective evaluation of the partially covered nitinol "Comvi" stent for malignant non hilar biliary obstruction* ELSEVIER Digestive Endoscopy 2012 Guido Costamagna



Aquilant Interventional

UK Distributors

Aquilant Interventional
Aquilant House, Units B1-B2
Bond Close, Kingsland Business Park
Basingstoke, Hampshire, RG24 8PZ

T: +44 (0) 845 6024 007

F: +44 (0) 1256 365486

E: contactus@aquilantinterventional.com

W: www.aquilantinterventional.com

