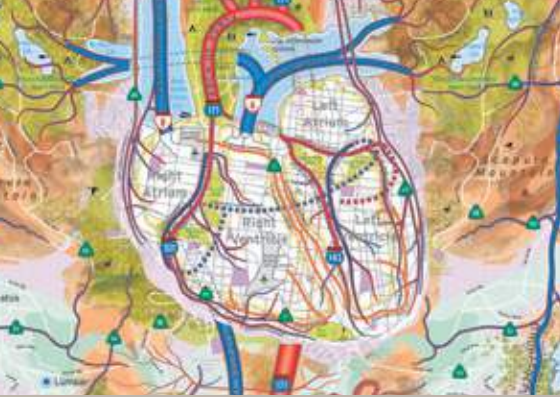
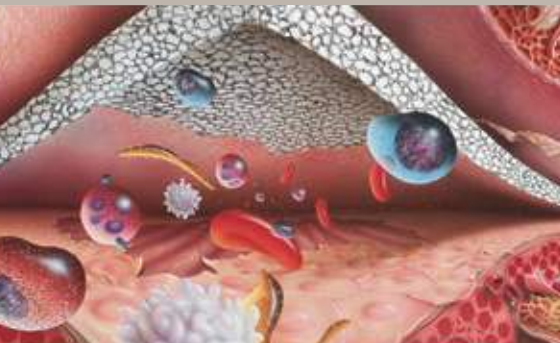




# Making History... in Cardiac Surgery


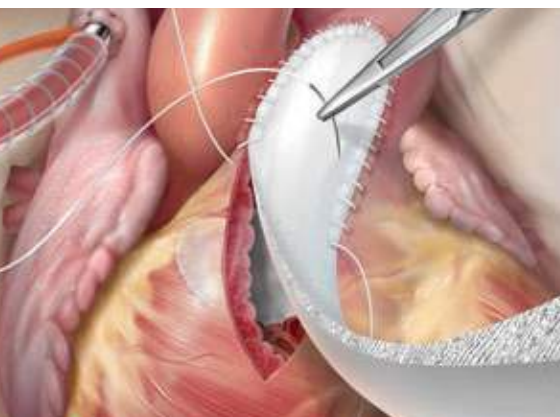
Gore Medical Products: 30 Years of Service. 25 Million Clinical Implants.



## ▶ **GORE PRECLUDE®** **Pericardial Membrane**

For reconstruction or repair of the pericardium

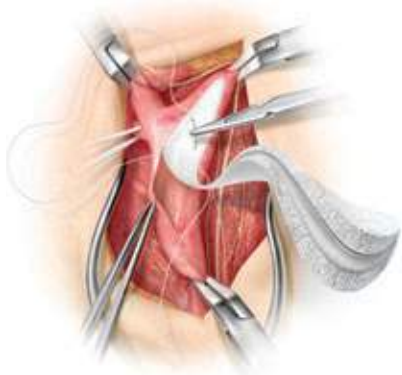
- 14 publications including over 2,500 patients<sup>1-14</sup>
- An average of 1.1% reported infection rate<sup>1-13</sup>
- Facilitates re sternotomies (n=178)<sup>1-7</sup>
  - Lower dissection time and blood use<sup>6, 9, 11</sup>
- < 1  $\mu\text{m}$  pore size inhibits tissue ingrowth
- Maintains a permanent plane of dissection
- Non-biological



## ▶ **GORE-TEX®** **Cardiovascular Patch**

For use in cardiovascular patching


- More than 10 published studies, including endarterectomy,<sup>15, 17</sup> septal defects,<sup>16, 18</sup> aortopulmonary windows,<sup>19</sup> atrioventricular canals,<sup>20, 21</sup> and aortoplasty<sup>22-25</sup>
- An average of 0.4% reported infection rate<sup>15, 16</sup>
- 22  $\mu\text{m}$  pore size enables tissue ingrowth
- Low thrombogenicity
- Non-biological



## GORE ACUSEAL Cardiovascular Patch

For use in cardiovascular patching

- Clinical experience since 1999<sup>26</sup>
- Hemostasis in three to five minutes in carotid endarterectomy<sup>26, 27</sup>
- 99% freedom from ipsilateral stroke at four years in carotid endarterectomy<sup>26</sup>
- Zero infections in a 200 patient study<sup>26</sup>
- 94% freedom from  $\geq 70\%$  restenosis at three years in carotid endarterectomy<sup>26</sup>
- 22  $\mu\text{m}$  pore size enables tissue ingrowth
- Fluoroelastomer layer designed to reduce suture line bleeding
- Non-biological



Side View 100x Magnification  
— 100 microns



**W. L. GORE & ASSOCIATES, INC.**  
Flagstaff, AZ 86004

**800.437.8181 (US)**  
**928.779.2771 (US)**  
**00800.6334.4673 (EU)**

For international contacts and additional product information, visit [goremedical.com](http://goremedical.com)

## References

1. Amato JJ, Cotroneo JV, Galdieri RJ, Alboliras E, Antillon J, Vogel RL. Experience with the polytetrafluoroethylene surgical membrane for pericardial closure in operations for congenital cardiac defects. *Journal of Thoracic & Cardiovascular Surgery* 1989;97(6):929-934.
2. Jacobs JP, Iyer RS, Weston JS, et al. Expanded PTFE membrane to prevent cardiac injury during re sternotomy for congenital heart disease. *Annals of Thoracic Surgery* 1996;62(6):1778-1782.
3. Leprince P, Rahmati M, Bonnet N, et al. Expanded polytetrafluoroethylene membranes to wrap surfaces of circulatory support devices in patients undergoing bridge to heart transplantation. *European Journal of Cardio-thoracic Surgery* 2001;19(3):302-306.
4. Loebe M, Alexi-Meskhisvili V, Weng Y, Hausdorf G, Hetzer R. Use of polytetrafluoroethylene surgical membrane as a pericardial substitute. *Texas Heart Institute Journal* 1993;20(3):213-217.
5. Mestres C-A, Comas JV, Ninot S, et al. The use of polyetherurethane urea (Mitrathane) and polytetrafluoroethylene (Gore-Tex) membranes for pericardial closure: initial clinical results. *Thai Journal of Surgery* 1986;7(4):125-128.
6. Minale C, Nikol S, Hollweg G, Mittermayer C, Messmer BJ. Clinical experience with expanded polytetrafluoroethylene Gore-Tex surgical membrane for pericardial closure: a study of 110 cases. *Journal of Cardiac Surgery* 1988;3(3):193-201.
7. Vitali E, Russo C, Tiziano C, Lanfranconi M, Bruschi G. Modified pericardial closure technique in patients with ventricular assist device. *Annals of Thoracic Surgery* 2000;69(4):1278-1279.
8. Bacaner TJ, Young JN, DeCampi WM, Hardy C. Pericardial substitute and emergency re sternotomy: life-saving combination. *Pediatric Cardiology* 1996;17(6):396-398.
9. Bezon E, Maguid YA, Gueret G, Choplain JN, Aziz AA, Barra JA. Wrapping of the left internal thoracic artery with an expanded polytetrafluoroethylene membrane. *Annals of Thoracic Surgery* 2006;81(1):383-385.
10. Bhatnagar G, Fremes SE, Christakis GT, Goldman BS. Early results using an ePTFE membrane for pericardial closure following coronary bypass grafting. *Journal of Cardiac Surgery* 1998;13(3):190-193.
11. Copeland JG, Arabia FA, Smith RG, Covington D. Synthetic membrane neo-pericardium facilitates total artificial heart explantation. *Journal of Heart & Lung Transplantation* 2001;20(6):654-656.
12. Kajiwara H, Hamada T, Ichikawa Y, Ishi M, Yamazaki I. Experience with expanded polytetrafluoroethylene (ePTFE Gore-Tex) surgical membrane for coronary artery grafting: does ePTFE surgical membrane predispose to postoperative mediastinitis? *Artificial Organs* 2004;28(9): 840-846.
13. Minale C, Hollweg G, Nikol S, Mittermayer CH, Messmer BJ. Closure of the pericardium using expanded polytetrafluoroethylene GORE-TEX surgical membrane: clinical experience. *Thoracic & Cardiovascular Surgeon* 1987;35(5):312-315.
14. Lahtinen J, Satta J, Lähde S, et al. Computed tomographic evaluation of retrosternal adhesions after pericardial substitution. *Annals of Thoracic Surgery* 1998;66(4):1264-1268.
15. Rhodes VJ. Expanded polytetrafluoroethylene patch angioplasty in carotid endarterectomy. *Journal of Vascular Surgery* 1995;22(6):724-731.
16. Hamid IA, Jothi M, Rajan S, Monro JL, Cherian KM. Transaortic repair of ruptured aneurysm of sinus of Valsalva. Fifteen-year experience. *Journal of Thoracic & Cardiovascular Surgeon* 1994;107(6):1464-1468.
17. AbuRahma AF, Hannay RS, Khan JH, Robinson PA, Hudson JK, Davis EA. Prospective randomized study of carotid endarterectomy with polytetrafluoroethylene versus collagen-impregnated Dacron (Hemashield) patching: perioperative (30-day) results. *Journal of Vascular Surgery* 2002;35(1):125-130.
18. Maile S, Kadner A, Turina MI, Pretre R. Detachment of the anterior leaflet of the tricuspid valve to expose perimembranous ventricular septal defects. *Annals of Thoracic Surgery* 2003;75(3):944-946.
19. Mert M, Paker T, Akcevin A, et al. Diagnosis, management, and results of treatment for aortopulmonary window. *Cardiology in the Young* 2004;14(5):506-511.
20. Backer CL, Mavroudis C, Alboliras ET, Zales VR. Repair of complete atrioventricular canal defects: results with the two-patch technique. *Annals of Thoracic Surgery* 1995;60(3):530-537.
21. Prêtre R, Dave H, Kadner A, Bettex D, Turina MI. Direct closure of the septum primum in atrioventricular canal defects. *Journal of Thoracic & Cardiovascular Surgery* 2004;127(6):1678-1681.
22. Backer CL, Paape K, Zales VR, Weigel TJ, Mavroudis C. Coarctation of the aorta. Repair with polytetrafluoroethylene patch aortoplasty. *Circulation* 1995;92: Supplement II:132-136.
23. Sade RM, Crawford FA, Hohn AR, Riopel DA, Taylor AB. Growth of the aorta after prosthetic patch aortoplasty for coarctation in infants. *Annals of Thoracic Surgery* 1984;38(1):21-25.
24. Yee ES, Soifer SJ, Turley K, Verrier ED, Fishman NH, Ebert PA. Infant coarctation: a spectrum in clinical presentation and treatment. *Annals of Thoracic Surgery* 1986;42(5):488-493.
25. Dodge-Khatami A, Backer CL, Mavroudis C. Risk factors for re coarctation and results of reoperation: a 40-year review. *Journal of Cardiac Surgery* 2000;15(6):369-377.
26. AbuRahma AF, Stone PA, Welch CA, Hofeldt MJ, Hass SM, Perry W. Prospective study of carotid endarterectomy with modified polytetrafluoroethylene (ACUSEAL) patching: early and late results. *Journal of Vascular Surgery* 2005;41(5):789-793.
27. AbuRahma AF, Stone PA, Flaherty SK, AbuRahma Z. Prospective randomized trial of ACUSEAL (Gore-Tex) versus Hemashield-Finesse patching during carotid endarterectomy: early results. *Journal of Vascular Surgery* 2007;45(5):881-884.