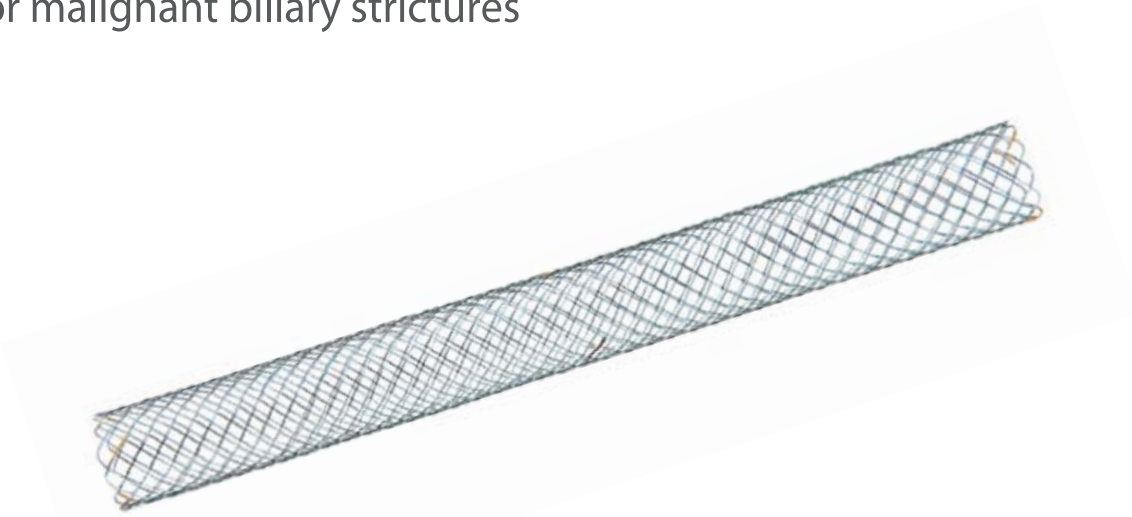




# S Biliary stent (Uncovered)

for malignant biliary strictures




## Feature

- **Fixed cell with braided construction**

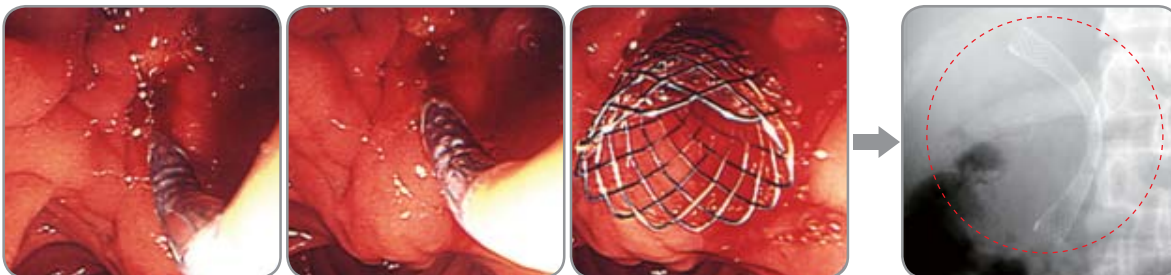
- Flexible and resistant to fracture

- **Atraumatic ends**

- Less hyperplasia at the edges



- **Radiopaque marker : 3(three) at both ends & 2(two) in the middle**



[Seoul Baek Hospital, Seoul, Korea]

### Released Articles

\* *Palliation of Malignant Biliary and Duodenal Obstruction with Combined Metallic Stenting*

Cardiovasc Intervent Radio(2007) 30: 1173-1177 Devrim Akinci MD, et al.

\* *Pneumoperitoneum Following Percutaneous Biliary Intervention: Not Necessarily a Cause for Alarm*

Candiovasc Intervent Radiol(2008) Suraj J, et al.



**Aquilant Interventional**

### UK Distributors

Aquilant Interventional  
Aquilant House, Units B1-B2  
Bond Close, Kingsland Business Park  
Basingstoke, Hampshire, RG24 8PZ

T: +44 (0) 845 6024 007  
F: +44 (0) 1256 365486  
E: [contactus@aquilantinterventional.com](mailto:contactus@aquilantinterventional.com)  
W: [www.aquilantinterventional.com](http://www.aquilantinterventional.com)